

## CASE REPORT

# Imaging of a Rare Case of Diaphragmatic Tumor

<sup>1</sup>Sowmya Anand, <sup>2</sup>Nitish Suresh, <sup>3</sup>Ajit K Reddy, <sup>4</sup>Anil K Shukla

## ABSTRACT

Primary tumors of the diaphragm are quite rare. About 150 cases have been reported in the literature. Fibrosarcomas are the most common malignant neoplasms of the diaphragm; however, only a few (less than 20) cases have been reported to date. We present a case of an extremely rare tumor of the diaphragm. A 65-year-old woman presented with history of vague upper abdominal pain since 2 months and distension for 2 weeks. Ultrasonography features were in favor of a mass arising from left dome of diaphragm with evidence of vascularity on Doppler; lesion was displacing spleen inferiorly. Contrast-enhanced computed tomography scan of the abdomen revealed a mass located in the region of the left dome of diaphragm and deriving blood supply from the branches of abdominal aorta. Surgical excision was planned, keeping in mind the diagnosis of a left diaphragmatic tumor. Laparotomy revealed a left diaphragmatic tumor growing caudally into the upper abdomen.

**Keywords:** Diaphragmatic tumor, Fibrosarcoma, Leiomyosarcoma, Mesothelioma, Rhabdomyosarcoma.

**How to cite this article:** Anand S, Suresh N, Reddy AK, Shukla AK. Imaging of a Rare Case of Diaphragmatic Tumor. *J Med Sci* 2017;3(1):25-27.

**Source of support:** Nil

**Conflict of interest:** None

## INTRODUCTION

Primary tumors of the diaphragm have a rare incidence and prevalence. Only about 150 cases have been reported in the literature to date. Most primary tumors of the diaphragm are benign. Of the malignant subgroup, fibrosarcoma appears to be the commonest.<sup>1</sup> Low-grade fibromyxoid sarcoma (LGFMS) is a unique subentity in the group of fibrosarcomas. These tumors are unique in their reappearance as metastases after significant time intervals.

<sup>1,2</sup>Resident, <sup>3</sup>Assistant Professor, <sup>4</sup>Professor

<sup>1-3</sup>Department of Radiodiagnosis, Kempegowda Institute of Medical Sciences, Bengaluru, Karnataka, India

<sup>4</sup>Department of Radiodiagnosis, RajaRajeswari Medical College and Hospital, Bengaluru, Karnataka, India

**Corresponding Author:** Anil K Shukla, Professor, Department of Radiodiagnosis, RajaRajeswari Medical College and Hospital Bengaluru, Karnataka, India, Phone: +91-9342508923, e-mail: shookla2007@yahoo.co.in

## CASE REPORT

A 65-year-old female patient presented with complaints of vague abdominal pain since 2 months with abdominal distension for 2 weeks.

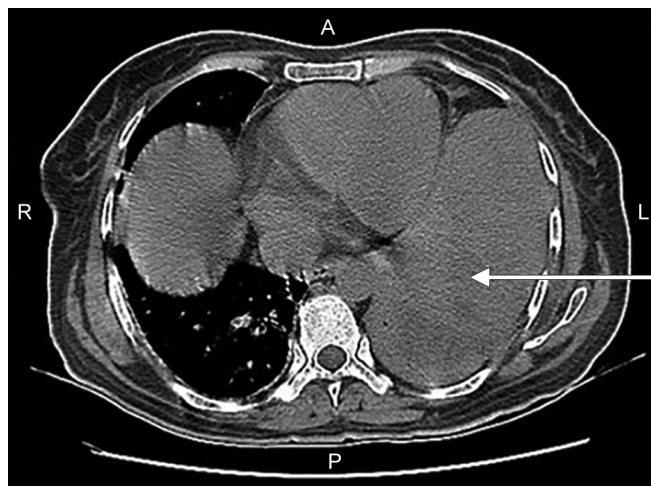
Her general condition was good and she has no other complaints. Her clinical and biochemical evaluation did not reveal anything significant.

She was evaluated first by ultrasonography and later with contrast-enhanced computed tomography (CECT) of the abdomen. A large heterogeneous lesion, probably arising from the left dome of diaphragm, was seen.

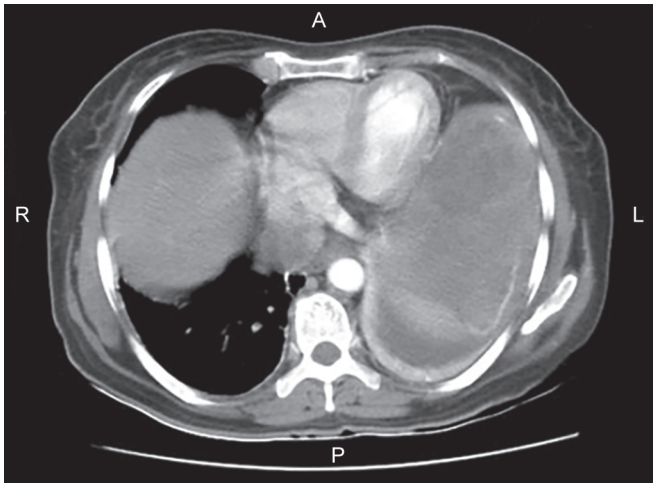
Ultrasonographic features were in favor of a mass arising from diaphragm. A hypoechoic solid mass lesion was noted in left hypochondrium displacing the spleen inferiorly. It is in continuity with the diaphragm. On Doppler, mild vascularity was noted.

The CECT abdomen showed a heterogeneous soft tissue mass lesion measuring approximately 13.2 × 6.5 × 16.5 cm in the left upper hypochondrium, appearing isodense to the muscle seen closely abutting the left dome of diaphragm with loss of fat plane (Fig. 1). Postcontrast study shows mild heterogeneous enhancement of the mass lesion (Fig. 2). Lesion is seen to derive blood supply from branches of abdominal aorta Fig. 3).

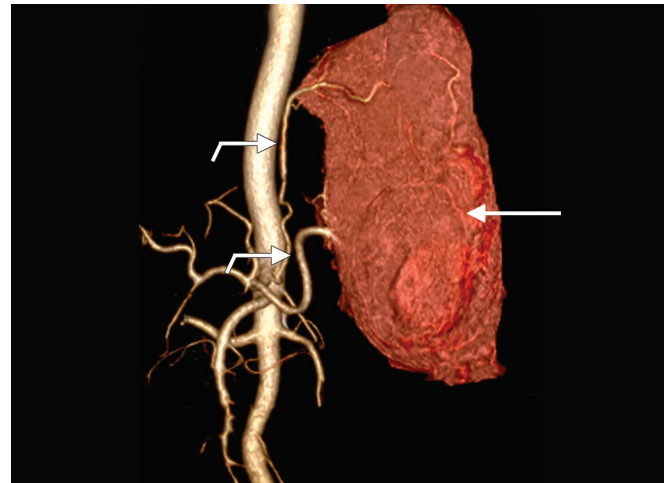
On laparotomy, a solid, rounded, gray tumor was found arising from the left diaphragm, compressing and splaying the entire left lobe of liver, which was adherent to the tumor medially. The upper border of the mass was attached to the inferior surface of the left



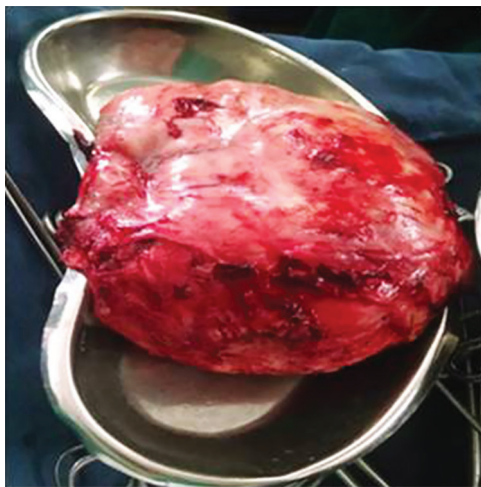**Fig. 1:** Plain CT axial image showing isodense mass lesion in close proximity with left dome of diaphragm measuring approximately 13.2 × 6.5 × 16.5 cm (AP × TRA × CC) (arrow)



**Fig. 2:** The CECT axial image showing heterogeneous enhancement of the lesion with few nonenhancing areas suggestive of necrosis (arrow)



**Fig. 3:** Virtual reality image of the kidney, ureter, and bladder region showing mass (arrow) lesion deriving blood supply from branches of abdominal aorta (bent Arrows)



**Fig. 4:** Gross specimen showing mass lesion resected from the left dome of diaphragm

diaphragm. The entire mass was excised along with the left lower three ribs from which it was inseparable. The superficial structures of the left chest wall were not involved. Local left supradiaphragmatic lymph nodes were also excised. The tumor was well encapsulated, firm, weighed approximately 2 kg, and measured 23 × 18 × 11 cm [anteroposterior (AP) × transverse (TRA) × craniocaudal (CC)] (Fig. 4).

Microscopy revealed a bland-appearing spindle cell tumor of low cellularity. The tumor showed contrasting fibrous and myxoid areas. The spindle cells demonstrated a focal swirling or whorled pattern. On high power, the tumor cells showed minimal pleomorphism without any mitosis. Focally, tumor cells appeared stellate shaped. Few areas showed curvilinear- or capillary-sized blood vessels with spindle cells encasing around them.

Immunohistochemistry revealed strong positive immunostaining of the spindle cells with vimentin and

focally for B-cell lymphoma 2 but negative for S100, smooth muscle antigen, desmin, epithelial membrane antigen, and CD34. Based on characteristic histomorphological features and immunohistochemistry results, a diagnosis of LGFMS was made.

Diaphragmatic tumors are rare and more than half are benign. Tumors arise from mesenchymal tissue because of their mesodermal origin. Direct extension from other intraabdominal or intrathoracic tumors can occur, commonly from mesothelioma, lung cancer, and hepatic carcinoma. Most primary tumors of the diaphragm are benign. Fibrosarcoma appears to be the commonest among the malignant subgroup.<sup>1</sup>

## DISCUSSION

Primary tumors of the diaphragm are very rare. The first diaphragmatic tumor was reported in 1868 by Grancher. About 150 cases have been reported in the literature since then. The majority of diaphragmatic tumors are benign. Most malignant tumors of the diaphragm are sarcomas of fibrous or muscular origin.

Fibrosarcomas are the commonest malignant neoplasms of the diaphragm. Diaphragmatic tumors still present as a diagnostic dilemma, and are difficult to diagnose preoperatively or without a pathological diagnosis.

Rhabdomyosarcoma has four histological subtypes: Pleomorphic, alveolar, botryoid, and embryonic. Most common is the embryonic type.<sup>1</sup>

Weber first described pleomorphic rhabdomyosarcoma in 1854, in Virchow's archives, occurring in the tongue of an aged man. Rakov in 1937 reported the first large series of this tumor, followed by Stout in 1946.<sup>2</sup>

Leiomyosarcoma of the diaphragm is an extremely rare entity. The diagnosis is more difficult in the early stages with a very poor prognosis. Surgery represents the only radical treatment of this tumor.<sup>3</sup>

The role of pulmonary diseases in the etiology of primary tumors of the diaphragm is not clear, but three cases suffered from tuberculosis,<sup>4</sup> asbestosis,<sup>5</sup> and anthracosilicosis,<sup>6</sup> respectively.

## CONCLUSION

In conclusion, this case highlights that an extrahepatic vascular supply may act as an indicator of the extrahepatic origin of a tumor showing indistinct fat planes from the liver. Also, although rare, diaphragmatic mesenchymal tumors should also be included in the differential of atypical-appearing hepatic or extrahepatic masses in the upper abdomen.

## REFERENCES

1. Thapar S, Ahuja A, Rastoqi A. Rare diaphragmatic tumor mimicking liver mass. *World J Gastrointest Surg* 2014 Feb;6(2):33-37.
2. Deniz PP, Kalac N, Ucoluk GO, Samurkasoglu B, Tastepi AI, Gulhan E, Demirag F. A rare tumor of the diaphragm: pleomorphic rhabdomyosarcoma. *Ann Thorac Surg* 2008 Jun;85(5):1802-1805.
3. Louzi A, Benelkhaat R, Finech B, Belaabidia B, Hakkou M, Elidrissi A. Leiomyosarcoma of the diaphragm: two case reports. *Internet J Surg* 2006;13(2):1-5.
4. McCoy WC. Leiomyosarcoma of the diaphragm. *South Med J* 1963 Jun;56(6):642-647.
5. Dionne GP, Beland JE, Wang NS. Primary leiomyosarcoma of the diaphragm of an asbestos worker. *Arch Pathol Lab Med* 1976 Jul;100(7):398.
6. Blondeel PN, Christiaens MR, Thomas J, Gruwez JA, Sciot R. Primary leiomyosarcoma of the diaphragm. *Eur J Surg Oncol* 1995 Aug;21(4):429-431.